

Case Study

Office Based Y-90, Increasing Access for mCRC Patients who are Candidates for SIRT | Michael Vitale, M.D., Interventional Radiology, ProHealth Care Associates | Jonathan Khodadadian, M.D., Nuclear Medicine, ProHealth Care Associates

Overview

Traditionally, Selective Internal Radiation Therapy (SIRT) using SIR-Spheres® Y-90 resin microspheres has been performed as an outpatient hospital procedure by the Interventional Radiologist who delivers the required dosage of around 10-20 million microspheres, under fluoroscopic guidance, to the patient via the hepatic artery that feeds the tumors in the liver. The microspheres are carried through the arterioles to lodge in the capillary bed of the tumors, emitting localized radiation with a mean penetration of 2.5 mm in tissue.

Since the expansion of enhanced office based imaging, there has been a gradual migration of SIRT into office based angio suites from the traditional outpatient hospital setting. This case study demonstrates the feasibility of performing the required pre-operative steps at multiple non-hospital locations. For example, when lung shunt nuclear imaging equipment is not available at the interventional radiology location, the necessary indications for use (IFU) can successfully be facilitated in advance of the procedure at an offsite location to provide the mCRC patient with access to SIRT.

Patient History

A 56-year-old male patient was diagnosed with metastatic colorectal cancer (mCRC) in May 2018 after routine colonoscopy. A large polyp was discovered during the colonoscopy in the descending colon and the patient underwent a hemicolectomy at that time. In July 2018, patient began FOLFOX (oxaliplatin, 5-Fluorouracil, leucovorin) chemotherapy to treat stage 4 mCRC. The hepatic metastases and primary lesion

decreased in size following the first cycle of chemotherapy, and FOLFOX was continued for 3 more cycles before the patient was considered for SIR-Spheres Y-90 resin microspheres.

In November 2018, scans demonstrated stabilization of 4 to 5 lesions on the right lobe of the liver and 1 lesion slightly decreasing. It was determined that the patient would undergo 2 more cycles of chemo before proceeding with SIRT or SIR-Spheres Y-90 resin microspheres treatment. A month later, while the patient's imaging appeared stabilized, his CEA levels were rising. Following a consult with the interventional radiology team for liver directed therapy, the patient was deemed a suitable candidate for SIRT with SIR-Spheres Y-90 resin microspheres, based on his ECOG status (0) and liver profile (bilirubin 0.34, Alkaline Phosphatase 103, AST 29, ALT 32).

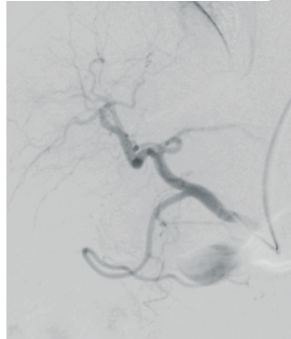
Procedure

In January 2019, the patient underwent a mapping procedure in preparation for the SIRT procedure and a CT scan the same day. Both procedures took place at ProHEALTH Care Associates' Lake Success Interventional Radiology location. In addition, the IFU for SIR-Spheres Y-90 resin microspheres require a lung shunt scan to determine the risk of non-target delivery of the microspheres, which are administered through the portal vein. While Nuclear Medicine was not available at the same location, the medical team collaborated to arrange needed lung shunt imaging at the Nuclear Medicine location for ProHEALTH Care Associates.

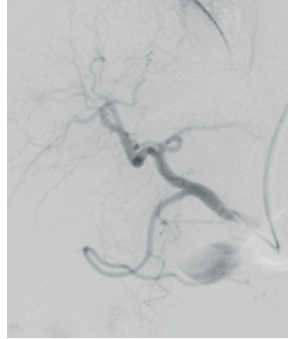
continued on next page

continued from previous page

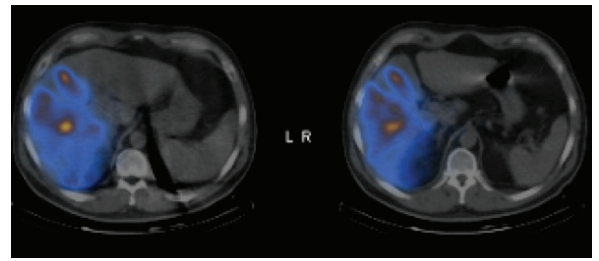
Following all indicated pre-operative procedures, the first SIRT procedure was performed on 1/16/19 to the right lobe of the liver. The team administered 27mCi in the form of SIR-Spheres® Y-90 resin microspheres to the liver tumors via the hepatic artery. The patient continued chemotherapy treatments during the timeframe in which the SIRT treatment was administered.



Y-90 Mapping Procedure performed on an OEC 9900 C-Arm (GE Healthcare)



Dose Delivery performed on OEC 9900 C-arm (GE Healthcare)



(SpectCT demonstrates enhancement of several lesions contained in the right lobe)

Conclusion

A patient with unresectable liver tumors who had multiple colorectal liver metastases was successfully treated with SIR-Spheres Y-90 resin microspheres. One of the benefits of SIRT using yttrium y-90 is that most patients with mCRC can continue their chemotherapy regimens without interruption, which was the case with this patient.

SIRT should be considered as a valid therapeutic option in the office-based setting for patients with chemotherapy-refractory, liver-limited or liver-dominant mCRC. With proper patient selection the procedure is well tolerated with a low incidence of severe complications.

Results

One month after the first SIRT treatment, the follow-up PET/CT scan in March 2019, showed a dramatic response to the SIR-Spheres Y-90 resin microspheres therapy in the right lobe with reduced evidence of active hepatic disease. The patient has continued with chemotherapy and will be re-evaluated with a PET/CT in May/June 2019.

About the Authors

Michael Vitale, M.D., is a board-certified interventional and diagnostic radiologist in the Department of Interventional Services at ProHEALTH Care Associates specializing in all fields of interventional radiology, including: interventional oncology, uterine fibroid embolization, the management of pelvic pain due to congestion syndrome, and the treatment of complex peripheral arterial and venous disease. Dr. Vitale graduated from New York Medical College and completed an internship in internal medicine at Long Island Jewish Medical Center/Albert Einstein College of Medicine. He also completed a diagnostic radiology residency at Westchester Medical Center and, subsequently, an interventional radiology fellowship at The New York Presbyterian Hospital/ Columbia College of Physicians and Surgeons. He is currently a member of the Radiological Society of North America, the American Board of Radiology, and the Society of Interventional Radiology.

Jonathan Khodadadian, M.D., practices Nuclear Medicine and is affiliated with ProHEALTH Care Associates, Montefiore Medical Center and Bay Ridge Medical Imaging in New York. He graduated from Tel Aviv University Sackler Faculty of Medicine in 2008 and has been in practice for 8 years. He completed a residency at Montefiore Medical Center.

SIR-Spheres® is a registered trademark of Sirtex SIR-Spheres Pty Ltd

Sirtex Medical Inc.
300 Unicorn Park Drive,
Woburn, MA 01801
888.474.7839

www.sirtex.com
2019 Sirtex Medical Inc.

153-U-0319

Indications for Use: SIR-Spheres Y-90 resin microspheres are indicated for the treatment of unresectable metastatic liver tumors from primary colorectal cancer with adjuvant intrahepatic artery chemotherapy (IHAC) of FUDR (Fluorouridine). **CAUTION:** Federal (USA) law restricts this device to sale by or on the order of a physician. Please consult the package insert for complete information on risks, side effects, warnings, precautions and patient selection criteria.

SIRTeX